

The Anatomy of the Corrugator Supercilii Muscle: Part II. Supraorbital Nerve Branching Patterns

Jeffrey E. Janis, M.D.
Ashkan Ghavami, M.D.
Joshua A. Lemmon, M.D.
Jason E. Leedy, M.D.
Bahman Guyuron, M.D.

Dallas, Texas; and Cleveland, Ohio

Background: This article focuses on delineation of supraorbital nerve branching patterns relative to the corrugator muscle fibers and identifies four branching patterns that help improve understanding of the local anatomy.

Methods: Twenty-five fresh cadaver heads (50 corrugator supercillii muscles and 50 supraorbital nerves) were dissected and the corrugator supercillii muscles isolated. After corrugator supercillii muscle measurement points were recorded for part I of the study, the supraorbital nerve branches were then traced from their emergence points from the orbit and dissected out to the defined topographical boundaries of the muscle. Nerve branching patterns relative to the muscle fibers were analyzed, and a classification system for branching patterns relative to the muscle was created.

Results: Four types of supraorbital nerve branching patterns were found. In type I (40 percent), only the deep supraorbital nerve division sent branches that coursed directly along the undersurface of the muscle. In type II (34 percent), branches emerging directly from the superficial supraorbital nerve were found in addition to the branches from the deep division. Type III (4 percent) included discrete branches from the superficial division, but none from the deep division. In type IV (22 percent), significant branching began more cephalad relative to the muscle and, therefore, displayed no specific relation to the muscle fibers.

Conclusions: Contrary to previous reports, both the deep and superficial divisions of the supraorbital nerve are intimately associated with corrugator supercillii muscle fibers. Four supraorbital nerve branching patterns from these divisions were found. Potential sites of supraorbital nerve compression were identified. This more detailed anatomical information may improve the safety and accuracy of performing complete corrugator supercillii muscle resection. (*Plast. Reconstr. Surg.* 121: 233, 2008.)

In part I of this study, we reported data on the topographical dimensions of the corrugator supercillii muscle relative to fixed bony landmarks.^{1,2} This allows for a more systematic and predictable surgical approach to precise corrugator supercillii muscle resection for both forehead rejuvenation and the surgical treatment of migraine headaches, which has been shown to be paramount to an optimal result.¹⁻⁷

From the Department of Plastic Surgery, The University of Texas Southwestern Medical Center, and the Division of Plastic and Reconstructive Surgery, Case Western Reserve University School of Medicine.

Received for publication December 3, 2006; accepted July 21, 2007.

Copyright ©2007 by the American Society of Plastic Surgeons

DOI: 10.1097/01.prs.0000299260.04932.38

Most migraine headaches have been theorized to be related to irritation, entrapment, and/or compression of peripheral nerve trigger points.⁸⁻¹³ The supraorbital and supratrochlear nerves have been implicated as the frontal trigger sites.^{8,9} This theory has been supported in part by the fact that improvement of symptoms has been demonstrated in a significant proportion of patients after chemodenervation of the corrugator supercillii muscle by botulinum toxin type A.^{8-12,14-16}

The supraorbital nerve and its intimate relationship with the corrugator supercillii muscle

Disclosure: None of the authors received financial benefit from any commercial entity in support of this article.

require further anatomical inspection. We hypothesize that the supraorbital nerve divisions demonstrate a more significant branching pattern and muscular relationship with respect to the corrugator supercilii muscle than previously reported.

RELEVANT ANATOMY

The supraorbital nerve is a purely sensory nerve that arises from the ophthalmic division (V_1) of the trigeminal nerve. It exits through a supraorbital notch 90 percent of the time, but it can also exit a true bony foramen located 1.5 cm cephalad to the supraorbital rim 10 percent of the time.¹⁷⁻²⁰ Beer et al.²¹ performed an extensive anatomical study on the exit point(s) of the supraorbital nerve and found a single exit point (either notch or foramen) in 84 percent of right orbits and 82 percent of left orbits. However, in 14 percent of right orbits and 16 percent of left orbits, more than one exit point was found.²¹

After exiting the supraorbital rim (through either a foramen or notch), the supraorbital nerve trunk divides into a superficial branch and a deep branch.^{17,18,20} The deep division of the nerve splits from the nerve trunk at the supraorbital notch in 5 percent to 10 percent of patients, but it has been noted that the deep branch can also branch out from a separate, more lateral foramen.¹⁷ The deep branch has a more consistent distribution and runs deep to the frontalis in a cephalad direction between the galea and periosteum in the lower half of the forehead to provide sensory innervation to the frontoparietal scalp.^{17,18} Its course parallels the temporal fusion line, traveling just medial to it.¹⁸ According to Knize,²² the deep division does not branch except for tiny “threadlike” strands extending to the underlying periosteum.

The superficial division divides into multiple smaller branches that penetrate the frontalis muscle and pass over the muscle as they travel toward the hairline to provide sensation to the forehead and anterior scalp. This pattern was seen in 90 percent of specimens evaluated by Knize.^{17,18} While three types of branching patterns of the supraorbital nerve deep branch have been described,¹⁷ these were not defined relative to the overlying musculature and were described as always running deep to or within the galea.

On the basis of extensive intraoperative observation, the senior author (B.G.) believes there to be significant branching relative to the corrugator supercilii muscle from both the deep and superficial supraorbital nerve divisions. Nerve fibers may be more closely associated with the cor-

rugator supercilii muscle fibers than previously described.

MATERIALS AND METHODS

Twenty-five fresh cadaver heads (50 corrugator muscles and 50 supraorbital nerves) were dissected using a cross-shaped incision centered over the radix, with the transverse component following the eyebrow arches (Fig. 1). None of the cadavers had previous trauma sustained to the anatomical regions to be dissected. All dissections were carried out under $3.8\times$ high loupe magnification. Adipocutaneous flaps were initially raised to avoid inadvertent injury to the underlying musculature or avulsion of cutaneous nerve branches from their nerve origins. The frontalis and depressor supercilii muscles were sharply dissected off of the corrugator supercilii muscle and elevated along with the skin flaps to complete the exposure. The full extent of the corrugator supercilii muscle was delineated and meticulously teased off of the interdigitating orbicularis oculi and frontalis muscles (Fig. 2). Standardized measurements of corrugator supercilii muscle dimensions were taken before proceeding to the supraorbital nerve dissection, and were reported in part I of this study.^{1,2} Of note, evaluation of supratrochlear nerve patterns revealed consistent branching within corrugator supercilii muscle fibers with no particular variations with respect to branching patterns or nerve-muscle associations; therefore, no further microdissection of this nerve was performed.

The inferior aspect of the corrugator supercilii muscle was reflected, revealing the origin of the supraorbital nerve trunk and its deep and superficial divisions, as well as their branches. Data and

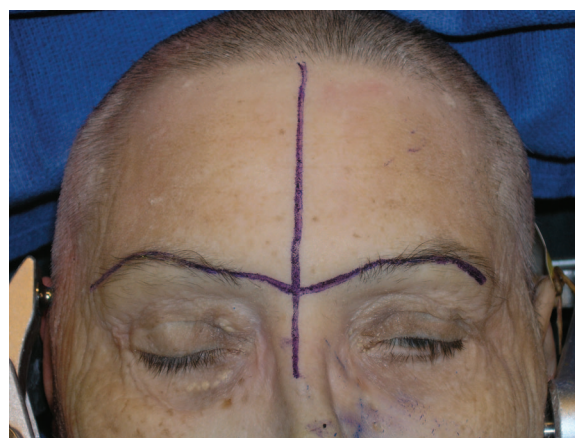

Fig. 1. Cross-shaped incision. Markings indicate incision placement and planned flap dissection.

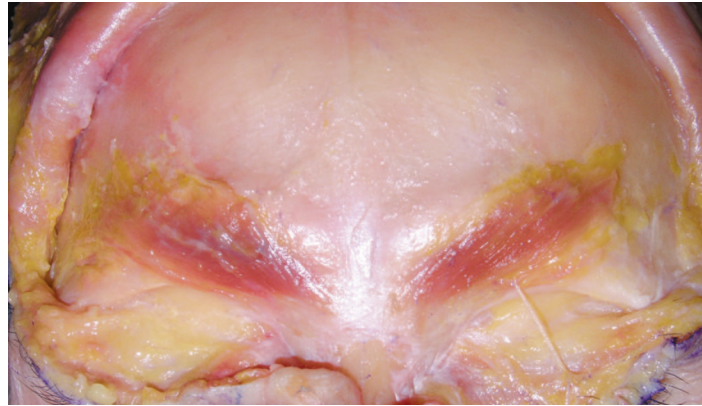


Fig. 2. Cadaver dissection depicting extent of corrugator supercilii muscle delineation and skeletonization.

observations were recorded as to the nerve fiber branching patterns along the corrugator supercilii muscle, the plane in which they ran, and the specific supraorbital nerve division from which they originated. A limited neurolysis was performed, when indicated, to facilitate better delineation of the finer nerve branches that coursed along the corrugator supercilii muscle. Dissection of the supraorbital nerve branches was limited to the most cephalad and lateral borders of the corrugator supercilii muscle, as only the supraorbital nerve branches associated with the corrugator muscle fibers were deemed relevant for this study. These corrugator supercilii muscle branches were designated as superficial supraorbital nerve–corrugator supercilii muscle (SON-S_{CSM}) or deep supraorbital nerve–corrugator supercilii muscle (SON-D_{CSM}) depending on the nerve division they arose from.

RESULTS

Four types of supraorbital nerve branching patterns were found relative to the corrugator supercilii muscle fibers (Table 1). Branching patterns were classified according to the nerve divisions they originated from (SON-S_{CSM} or SON-D_{CSM}). It should be noted that while the designated supraorbital nerve division commonly sent a single

dominant corrugator-related nerve branch, finer nerve fibers (seen more often from the superficial branch of the nerve) were occasionally seen, but always from the same division. For simplification, finer nerve branches will not be included as part of a subclassification.

In type I (40 percent), the deep supraorbital nerve division sent a single branch that coursed directly along the undersurface of the corrugator supercilii muscle (Fig. 3). In type II (34 percent), branches from the superficial supraorbital nerve were observed in addition to nerve fibers from the deep division (Fig. 4). Type III (4 percent) displayed discrete corrugator supercilii muscle–related branches from the superficial division, but none from the deep division (Fig. 5). Type IV displayed no significant branching relative to the corrugator supercilii muscle mass (Fig. 6 shows the absence of corrugator supercilii muscle–related supraorbital nerve branching). In the type IV pattern, branching (not related to the corrugator supercilii muscle fibers) was noted to arise mostly from the superficial division, but only after it passed the most cephalad portion of the corrugator supercilii muscle, while the deep division demonstrated no branches.

When a bony notch was present, there was occasionally a taut fibrous band that formed the

Table 1. Supraorbital Nerve Branching Classification

Classification	Branch Origin	Right	Left	Overall
Type I	Deep division	10	9	20/50 (40%)
Type II	Deep and superficial division	9	8	17/50 (34%)
Type III	Superficial division, no deep division	1	1	2/50 (4%)
Type IV*	No relation to CSM	5	5	11/50 (22%)

CSM, corrugator supercilii muscle.

*Branching usually began more cephalad relative to the corrugator supercilii muscle mass.

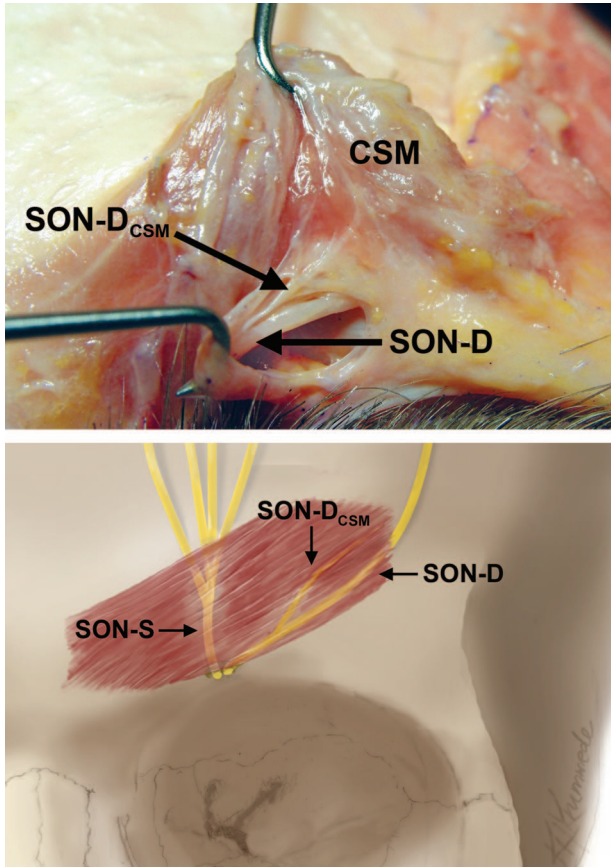


Fig. 3. Type I supraorbital nerve branching pattern. *SON-D*, deep division of the supraorbital nerve; *SON-D_{CSM}*, branching fibers from the deep division of supraorbital nerve; *CSM*, corrugator supercilii muscle. (Below) *SON-D* branching was simplified for illustration purposes. All illustrations will demonstrate the most common branching relative to the supraorbital nerve division, with only one fiber from the respective supraorbital nerve division.

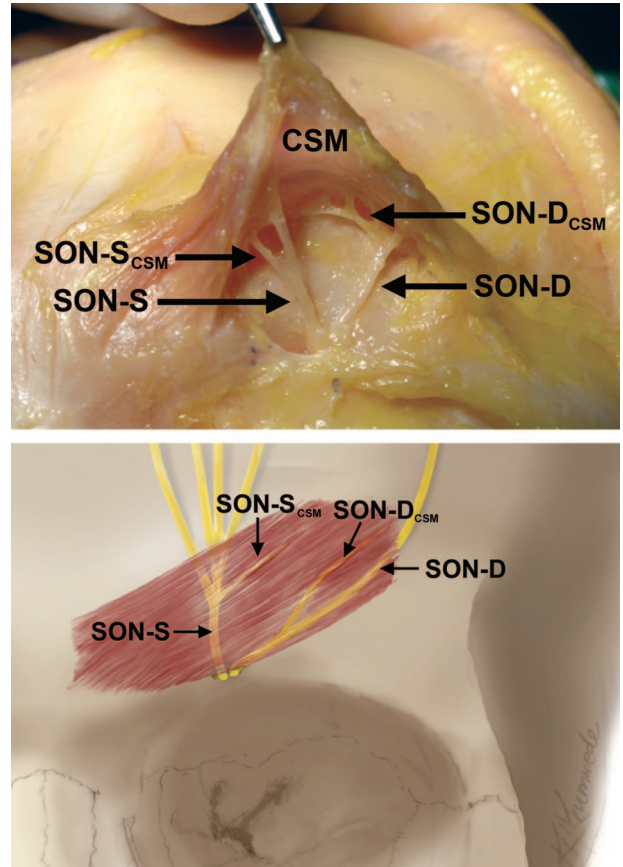


Fig. 4. Type II supraorbital nerve branching pattern. *SON-S*, superficial division of the supraorbital nerve; *SON-S_{CSM}*, branch fiber from *SON-S* relevant to the corrugator supercilii muscle; *CSM*, corrugator supercilii muscle; *SON-D*, deep division of the supraorbital nerve; *SON-D_{CSM}*, branch from deep division of supraorbital nerve.

anterior border of the supraorbital nerve notch and held the nerve trunk (or divisions) against the frontal bone. Some nerve branches were seen to be circumferentially enveloped by corrugator muscle fibers at some point along their course, but this was not a consistent finding. Interestingly, the specific branch (or branches) that was associated with the corrugator muscle fibers always coursed parallel to or nearly parallel to the direction of these muscle fibers. A trend was observed in which supraorbital nerve branches from both the deep and superficial divisions became progressively more superficial during their course away from their bony origin. These superficial branches were commonly present at the anatomical borders of the corrugator muscle, where muscular insertion points and interdigitations occur.

DISCUSSION

Successful forehead rejuvenation and surgical deactivation of frontal trigger sites of migraine headaches both require corrugator supercilii muscle resection. Knowledge of the exact course of the supraorbital nerve along the corrugator muscle may assist in a more safe and effective approach to forehead rejuvenation by coronal, transpalpebral, or endoscopic approaches.

Four patterns of supraorbital nerve branching were found (Fig. 7). Specific nerve branches that were invested by the corrugator muscle seemed to run parallel with the muscle fibers after they split off from the superficial and deep divisions. This observation may influence corrugator supercilii muscle dissection techniques to avoid unnecessary nerve sacrifice.

In type I (40 percent) only the deep supraorbital nerve division sent branches (*SON-D_{CSM}*) that

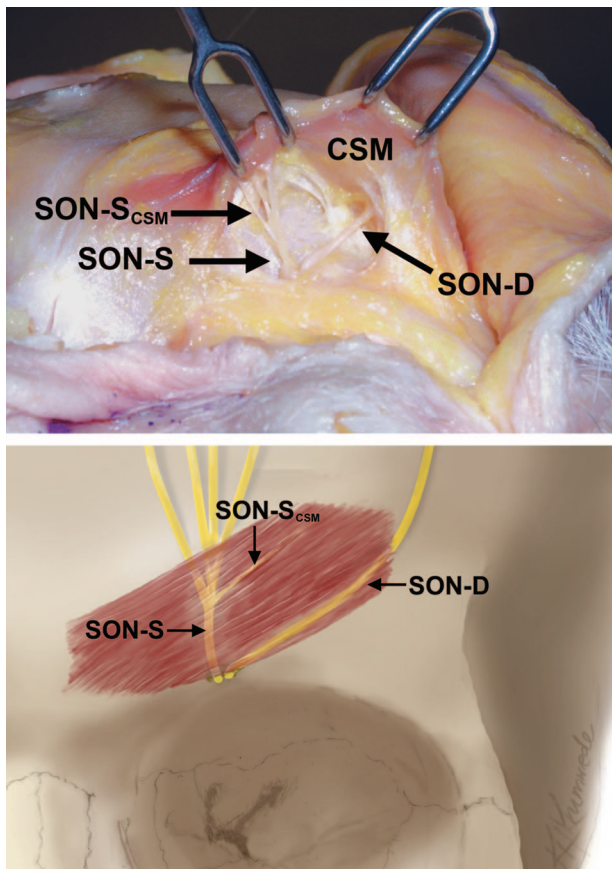


Fig. 5. Type III supraorbital nerve branching pattern. *SON-S*, superficial division of the supraorbital nerve; *SON-S_{CSM}*, branch from the superficial division of the supraorbital nerve; *CSM*, corrugator supercilii muscle; *SON-D*, deep division of the supraorbital nerve.

coursed directly along the undersurface of the corrugator supercilii muscle. Distinct branches (*SON-S_{CSM}*) emerging directly from the superficial supraorbital nerve were found in addition to those arising from the deep division in type II (34 percent). In type III (4 percent), nerve patterns included discrete branches from the superficial division (*SON-S_{CSM}*), but none from the deep division. In type IV (22 percent), significant branching occurred at a more cephalad location with respect to the corrugator supercilii mass; therefore, no branches specific to the corrugator muscle fibers were observed. Therefore, 74 percent of the time (types I and II), a corrugator muscle-related supraorbital nerve branch was shown to arise from the deep division, while 22 percent (type IV) of the time, no direct correlation between the supraorbital nerve and the corrugator supercilii muscle exists.

Although supraorbital nerve branches were not seen to perforate all the way through the cor-

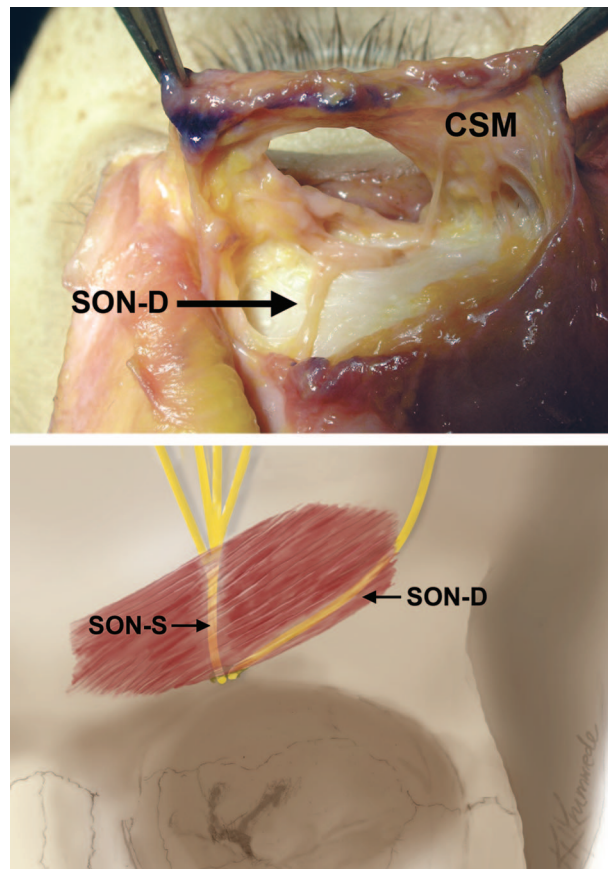


Fig. 6. Type IV supraorbital nerve branching pattern. (Above) Note the change in orientation. Represented view is looking down at the retracted corrugator supercilii muscle from a cephalad-to-caudal direction. (Above and below) Branching from the superficial division of the supraorbital nerve starts more cephalad relative to the corrugator supercilii muscle than other branching patterns. *SON-S*, superficial division of the supraorbital nerve; *CSM*, corrugator supercilii muscle; *SON-D*, deep division of the supraorbital nerve.

rugator supercilii muscle fibers, they did change their direction as they coursed further from their respective parent supraorbital nerve division(s), taking on a slightly more parallel orientation with respect to the corrugator muscle fibers.

Detailed knowledge of the potential sites of nerve compression may be as important in the treatment of migraine headaches as it has been in upper extremity. Interestingly, whenever a supraorbital nerve notch was seen, there was occasionally a fibrous band located anterior to the nerve trunk, which constrained it against the bony notch. Most often, the supraorbital nerve had already split into its deep and superficial divisions as it emerged from this point. This band could potentiate further nerve irritation and/or compression, regardless of the reason.

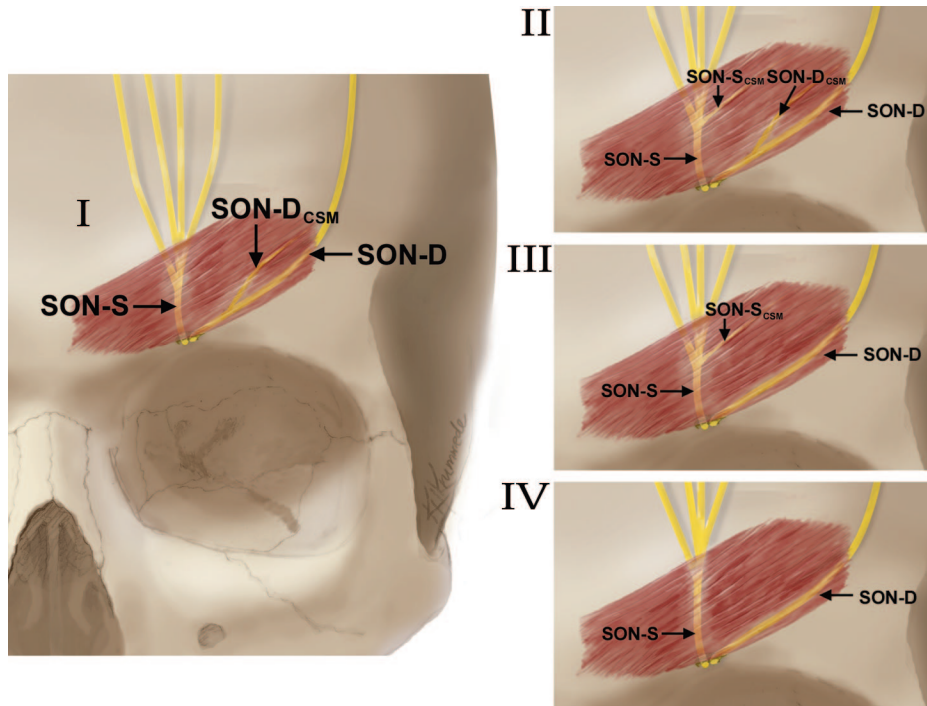


Fig. 7. Summary of supraorbital nerve branching pattern classification. (Left) Type I supraorbital nerve branching pattern, the most common type (enlarged). (Right) Types II through IV. SON-S, superficial division of the supraorbital nerve; SON-S_{CSM}, branch from the superficial division of the supraorbital nerve; SON-D, deep division of the supraorbital nerve; SON-D_{CSM}, branch from the deep division of the supraorbital nerve.

Immediately cephalad to this point is the inferior free border of the corrugator supercilii muscle and, laterally, the inferolateral interdigitation with the orbicularis oculi muscle. The free border of the corrugator supercilii muscle is surrounded by a galeal fat “glide plane,”²² and nerve compression here may be less common due to the ample soft-tissue cushion, unless there has been prior inflammation or trauma.²³ However, the location of the deep division of the supraorbital nerve at the site of corrugator supercilii muscle–orbicularis oculi interdigitation may be more susceptible to nerve compression, particularly with repetitive muscle contraction and increased muscle bulk. This can be observed clinically when the corrugator supercilii muscle contracts, as the medially directed pull of the muscle translates to the orbicularis oculi beyond the temporal fusion line.

Overall, the deep division may be more susceptible to compression at the lower portion of the frontal bone, where it travels against the periosteum to eventually course more medial to the temporal fusion line. Any branches that arise from the more adherent portion of the deep supraorbital nerve division must, by necessity, change their course to a more superficial one as they

course along the more superficially located corrugator supercilii muscle fibers. This deviation and change of plane from the firmly attached deep division is the next potential site of nerve compression.

Moving toward the hairline, another possible site of supraorbital nerve (and supratrochlear nerve) compression is the muscular interdigitation(s) of the corrugator supercilii muscle with the frontalis and medial orbicularis oculi muscles. Nerve branches may be compressed between the vertically oriented frontalis and orbicularis fibers and the nearly transversely oriented corrugator muscle fibers, where opposing muscular forces may create torquing forces on any of the nerve fibers.

CONCLUSIONS

Clarification of the nerve-muscle interactions between the corrugator supercilii muscle and supraorbital nerve has been established. While classification systems are sometimes difficult to apply to the clinical setting, recognition of the various supraorbital nerve branching patterns and their frequency may assist the surgeon in safer and more systematic corrugator muscle

dissection/resection techniques for forehead rejuvenation and migraine surgery.

From part II, we can conclude that (1) supraorbital nerve compression implicated in migraine etiology may exist at specific points along the supraorbital nerve path in relation to the corrugator supercilii muscle and its anatomical borders; (2) 78 percent of the time, supraorbital nerve branching begins closer to the supraorbital nerve bony origin, allowing for more significant investment by the corrugator supercilii muscle; (3) 22 percent of the time, no supraorbital nerve branching relative to the corrugator supercilii muscle could be established, since branching occurred more cephalad relative to the bulk of the corrugator muscle; (4) while some corrugator supercilii muscle fibers were noted to encircle branches of the supraorbital nerve, none actually perforated through the muscle, and supraorbital nerve bony exits that included a notch sometimes demonstrated a firm fibrous band that served as the anterior constraint of the nerve, limiting its mobility at the bony notch.

Interestingly, the distribution frequency of supraorbital nerve branching relative to the corrugator supercilii muscle seems to correlate with the success rate of migraine treatment by complete corrugator resection.⁸ A study by Guyuron et al.⁸ showed complete or significant amelioration of migraine headaches in 79.5 percent of patients after corrugator resection. This is similar to the 78 percent supraorbital nerve branching frequency (types I, II, and III) found in the current study, in which the supraorbital nerve and corrugator supercilii muscle are closely associated. It is plausible that those patients who do not experience a significant improvement in migraine headaches may exhibit type IV supraorbital nerve branching, in which nerve branches and corrugator muscle fibers are not intimately related.

Future studies may serve to further delineate correlations among specific branching patterns, anatomical points of compression, and migraine headache symptomatology.

Jeffrey E. Janis, M.D.

Department of Plastic Surgery
University of Texas Southwestern Medical Center
1801 Inwood Road
Dallas, Texas 75390-9132
Jeffrey.Janis@utsouthwestern.edu

ACKNOWLEDGMENTS

The authors thank Rod J. Rohrich, M.D., for his generosity in donating the cadaver specimens used in

this study. They also extend their deep appreciation to Kim A. Hoggatt-Krumwiede and Holly Smith for their talent and assistance with the images used in this study.

REFERENCES

1. Ghavami, A., Janis, J. E., Lemmon, J. A., Leedy, J. E., and Guyuron, B. The corrugator supercilii muscle: An anatomic reappraisal. Presented at the American Society for Aesthetic Plastic Surgery/Aesthetic Society Education and Research Foundation Annual Meeting (Gaspar W. Anastasi Award Presentation), Orlando, Fla., April 23, 2006.
2. Janis, J. E., Ghavami, A., Lemmon, J. A., Leedy, J. E., and Guyuron, B. The anatomy of the corrugator supercilii muscle: Part I. Corrugator topography. *Plast. Reconstr. Surg.* 120: 1647, 2007.
3. Guyuron, B. Endoscopic forehead rejuvenation: Limitations, flaws, and rewards. *Plast. Reconstr. Surg.* 117: 1121, 2006.
4. Guyuron, B., Michelow, B. J., and Thomas, T. Corrugator supercilii muscle resection through blepharoplasty incision. *Plast. Reconstr. Surg.* 95: 691, 1995.
5. Knize, D. M. Transpalpebral approach to the corrugator supercilii and procerus muscles. *Plast. Reconstr. Surg.* 95: 52, 1995.
6. Walden, J. L., Brown, C. C., Klapper, A. J., Chia, C. T., and Aston, S. J. An anatomical comparison of transpalpebral, endoscopic, and coronal approaches to demonstrate exposure and extent of brow depressor muscle resection. *Plast. Reconstr. Surg.* 116: 1479, 2005.
7. Guyuron, B. An anatomical comparison of transpalpebral, endoscopic, and coronal approaches to demonstrate exposure and extent of brow depressor muscle resection (Discussion). *Plast. Reconstr. Surg.* 116: 1488, 2005.
8. Guyuron, B., Varghai, A., Michelow, B. J., Thomas, T., and Davis, J. Corrugator supercilii muscle resection and migraine headaches. *Plast. Reconstr. Surg.* 106: 429, 2000.
9. Guyuron, B., Kriegler, J. S., Davis, J., and Amini, S. B. Comprehensive surgical treatment of migraine headaches. *Plast. Reconstr. Surg.* 115: 1, 2005.
10. Mosser, S. W., Guyuron, B., Janis, J. E., and Rohrich, R. J. The anatomy of the greater occipital nerve: Implications for the etiology of migraine headaches. *Plast. Reconstr. Surg.* 113: 693, 2004.
11. Dash, K. S., Janis, J. E., and Guyuron, B. The lesser and third occipital nerves and migraine headaches. *Plast. Reconstr. Surg.* 115: 1752, 2005.
12. Totonchi, A., Pashmini, N., and Guyuron, B. The zygomaticotemporal branch of the trigeminal nerve: An anatomical study. *Plast. Reconstr. Surg.* 115: 273, 2005.
13. Austad, E. D. Comprehensive surgical treatment of migraine headaches (Discussion). *Plast. Reconstr. Surg.* 115: 1759, 2005.
14. Binder, W. J., Brin, M. F., Blitzer, A., Schoenrock, L. D., and Pogoda, J. M. Botulinum toxin A (BTX-A) for the treatment of migraine headaches: An open-label study. *Otolaryngol. Head Neck Surg.* 123: 669, 2000.
15. Dodick, D. W. Botulinum neurotoxin for the treatment of migraine and other primary headache disorders: From bench to bedside. *Headache* 43(Suppl. 1): S25, 2003.

16. Mathew, N. T., and Kaup, A. O. The use of botulinum toxin type A in headache treatment. *Curr. Treat. Options Neurol.* 4: 365, 2002.
17. Knize, D. M. *The Forehead and Temporal Fossa: Anatomy and Technique*. Philadelphia: Lippincott Williams & Wilkins, 2001. Pp. 28–44.
18. Knize, D. M. A study of the supraorbital nerve. *Plast. Reconstr. Surg.* 96: 564, 1995.
19. Cuzalina, A. L., and Holmes, J. D. A simple and reliable landmark for identification of the supraorbital nerve in surgery of the forehead: An in vivo anatomical study. *J. Oral Maxillofac. Surg.* 63: 25, 2005.
20. Williams, P. L., Warwick, R., Dyson, M., and Bannister, L. H. (Eds.). *Gray's Anatomy*, 37th Ed. London: Churchill Livingstone, 1989. P. 1100.
21. Beer, G. M., Putz, R., Mager, K., Schumaker, M., and Keil, W. Variations of the frontal exit of the supraorbital nerve: An anatomic study. *Plast. Reconstr. Surg.* 102: 334, 1998.
22. Knize, D. M. Muscles that act on glabellar skin: A closer look. *Plast. Reconstr. Surg.* 105: 350, 2000.
23. Ramirez, O. M., and Pozner, J. N. Endoscopically assisted supraorbital nerve neurolysis and correction of eyebrow asymmetry. *Plast. Reconstr. Surg.* 100: 755, 1997.

Online CME Collections

This partial list of titles in the developing archive of CME article collections is available online at www.PRSJournal.com. *These articles are suitable to use as study guides for board certification, to help readers refamiliarize themselves on a particular topic, or to serve as useful reference articles. Articles less than 3 years old can be taken for CME credit.*

Cosmetic

- The Silicone Gel-Filled Breast Implant Controversy: An Update**—Arshad R. Muzaffar and Rod J. Rohrich
Understanding the Nasal Airway: Principles and Practice—Brian K. Howard and Rod J. Rohrich
Lateral Canthal Anchoring—Clinton McCord et al.
Male Rhinoplasty—Rod J. Rohrich et al.
The Cosmetic Use of Botulinum Toxin (October 2003 Supplement)—Rod J. Rohrich et al.
Thrombolytic Therapy following Rhytidectomy and Blepharoplasty—Stephanie L. Mick et al.
Current Concepts in Aesthetic Upper Blepharoplasty—Rod J. Rohrich et al.
Breast Augmentation: Cancer Concerns and Mammography—A Literature Review—Michael G. Jakubietz et al.
Prevention of Venous Thromboembolism in the Plastic Surgery Patient—Steven Paul Davison et al.
Breast Augmentation—Scott L. Spear et al.
Otoplasty: Sequencing the Operation for Improved Results—James Hoehn and Salman Ashruf
Thromboembolism in Plastic Surgery—Daniel Most et al.
Otoplasty—Jeffrey E. Janis et al.
Fire in the Operating Room: Principles and Prevention—Stephen P. Daane and Bryant A. Toth
Patient Safety in the Office-Based Setting—J. Bauer Horton et al.
Frequently Used Grafts in Rhinoplasty: Nomenclature and Analysis—Jack P. Gunter et al.
Injectable Soft-Tissue Fillers: Clinical Overview—Barry L. Eppley and Babak Davdand